

CHAPTER 80

Surgical Airway, Cricothyroidotomy, and Tracheotomy: Procedures, Complications, and Outcome

Rade B. Vukmir, MD • Ake Grenvik, MD, PhD •
Carl-Eric Lindholm, MD, PhD

Emergency laryngotracheal intubation is efficacious in approximately 97% of cases.¹ Thus, a surgical airway is needed in only 3% of such emergencies.² A summary of indications and contraindications for choice of airway access is presented in Table 80-1.

The need for an immediate surgical airway is evaluated in light of difficulties associated with emergency intubation (e.g., presence of laryngotracheal trauma or a foreign body lodged in the pharyngolaryngeal area). The surgical airway is also considered emergently in cases of suspected cervical spine fracture or severe anatomic deformity associated with oromaxillofacial or laryngeal trauma. Preoperative intubation of patients with known cervical fracture under optimum conditions in one investigation demonstrated new neurologic deficits in 1% to 2% of the patients with no differences based on technique (awake vs. with induction) or route (oral vs. nasal).³ According to one report,⁴ most cervical fractures encountered today occur in motor vehicle accidents (61%), with the following distribution: C-1, 7.1%; C-2, 12%; C-3, 5.7%; C-4, 15.0%; C-5, 29.2%; C-6, 27.0%; C-7, 3.5%. These patients were intubated in the operating room by nasal (71%) or oral (22%) routes, in the emergency department (6%), or in the prehospital realm (1%), all successfully without new neurologic deficit.⁴ In another study of blunt trauma, the incidence of cervical fracture was approximately 6% of all patients; 49% of these patients were intu-

bated orally and 47% were intubated nasally, leaving 4% who were treated with cricothyroidotomy.⁵

The presence of severe laryngotracheal trauma may require immediate establishment of a surgical airway. Such trauma occurs more commonly with penetrating injury (65%) and is associated with airway compromise (43%) and significant mortality (12%).⁶ The neck injury may be localized to the larynx itself, presenting with stridor and/or dysphonia as a result of edema, hematoma, laceration, and vocal cord dysfunction. Injury to the cervical trachea often presents with subcutaneous emphysema. Rupture of the intrathoracic trachea is suspected in the presence of pneumomediastinum or hemoptysis. Laryngeal injury is a relative contraindication to cricothyroidotomy and both oral and nasal intubation for extended periods. This situation remains the only indication for "emergency" tracheostomy, a procedure that is often time consuming even in expert hands.⁶ Therefore, preceding tracheal intubation to provide a guaranteed patent airway, if possible, is preferred even for this type of emergency tracheostomy.

When surgical airway is required emergently, cricothyroidotomy is the procedure of choice, except in patients with laryngeal trauma. Cricothyroidotomy has a higher success rate compared with tracheostomy and better patient neurologic outcome based primarily on less time required for the procedure.⁷ However, as a group, patients requiring an emergency surgical airway have a relatively high mortality.⁸

LARYNGEAL ANATOMY

The thyroid cartilage is the most readily identified laryngeal structure; it is located superior to the cricoid cartilage, to which it is connected by the cricothyroid joints and membrane (Fig. 80-1). This cricothyroid membrane occupies a trapezoidal area of approximately 3 cm² and has a 5- to 12-mm vertical height.^{9, 10} Adjacent vascular structures may include the overlying pyramidal lobe from the thyroid isthmus and small branches of the superior thyroidal arteries. Through another short, fibrous connection, the cricoid cartilage is united with the first tracheal cartilage. Sensory innervation to the larynx is provided mainly by the superior

TABLE 80-1. Artificial Airway Categories

| <i>Intubation</i> | <i>Surgical Cricothyroidotomy</i> | <i>Percutaneous Catheter Cricothyroidotomy or Tracheotomy</i> | <i>Surgical Tracheotomy</i> |
|------------------------------------|---|---|----------------------------------|
| <i>Indications</i> | | | |
| General anesthesia | Failed intubation | Failed intubation | Failed cricothyroidotomy |
| Respiratory arrest | Upper airway obstruction | Cervical fracture | Upper airway obstruction |
| Airway obstruction | Secretion retention | Partial airway obstruction | Long-term mechanical ventilation |
| Respiratory distress | Medium-term mechanical ventilation | Pharyngeal foreign body | Difficult weaning |
| Hemorrhage | Respiratory failure after recent sternotomy | | ETT laryngeal injury |
| Secretion retention | Cervical fracture | | Speech capability |
| Pulmonary contusion | Facial trauma (severe) | | Need for oral intake |
| Facial trauma (moderate) | Emergency airway | | Psychosocial benefit |
| Penetrating neck trauma | | | Oromaxillofacial trauma |
| Cardiac instability | | | Pharyngeal/glottic edema |
| Cardiac arrest | | | Nasal/oral/laryngeal hemorrhage |
| Coma | | | Neurologic deficit |
| <i>Contraindications</i> | | | |
| Anatomic difficulty | Laryngeal infection | Complete airway obstruction | Recent sternotomy |
| Coagulopathy (nasal) | Laryngeal trauma | Pediatric patients (relative) | Emergency airway |
| Facial fracture (nasal) | Intubation (>3 days) | Laryngeal trauma (relative) | |
| Cervical spine fracture (relative) | Pediatric patients (relative) | | |
| | Coagulopathy | | |

Abbreviation: ETT = endotracheal tube.

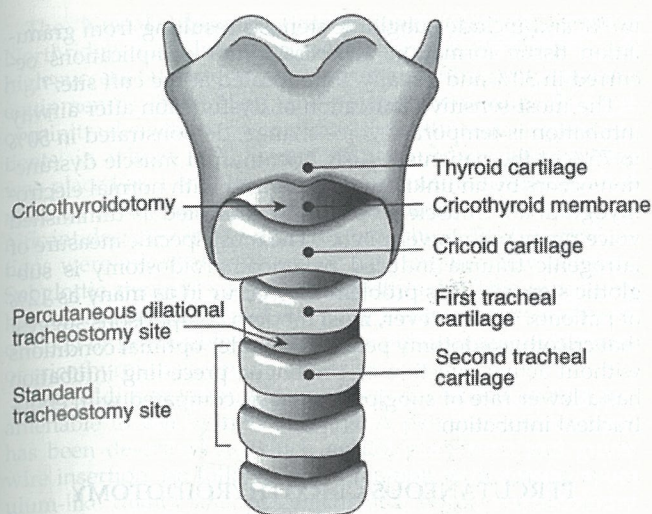


Figure 80-1. The laryngeal anatomy.

laryngeal nerves, whereas the recurrent laryngeal nerves provide motor innervation to the small laryngeal muscles except the cricothyroid muscles, which are supplied by the motor branches of the superior laryngeal nerves.

CRICOTHYROIDOTOMY

Historic Background

The modern history of cricothyroidotomy begins with the classic works of Chevalier Jackson, whose 30-year experience in treatment of laryngostenosis indicated that 93% of all complications occurred with what he referred to as "high tracheostomy" but with only 20% involving the cricothyroid membrane.¹¹ Thus, this valuable surgical airway technique was viewed with disfavor until the important review of cricothyroidotomy published by Brantigan and Grow in 1976. They reported a complication rate of only 6% in a large series, none of which was severe.¹²

Indications

The indications for cricothyroidotomy vary, but the technique is useful in any condition in which conventional intubation is not immediately successful. The technique is suitable for both emergent and elective situations (see Table 80-1). Contraindications are relative because most of these patients are in dire need of airway control. The procedure itself is simple to perform but optimized by meticulous technique (e.g., as follows):

PROCEDURE

1. *Position:* Neck hyperextension is desirable using a towel roll beneath the shoulders. The head must remain supported by the operating room table.
2. *Stabilization:* The nondominant hand stabilizes laryngeal cartilage with the index finger in the superior notch and the thumb and forefinger laterally.
3. *Cutaneous incision:* Although a horizontal incision is preferred when anatomic structures are easily identified, a vertical incision performed in the midline allows better landmark identification, greater chance of locating the cricothyroid membrane, and less bleeding, but healing is cosmetically inferior to the horizontal incision.
4. *Cricothyroid incision:* A horizontal stab incision through the cricothyroid membrane is performed with the knife directed

slightly upward to avoid unintentional injury of the posterior tracheal wall.

5. *Stabilization:* An assistant with superior and inferior skin hooks will optimize visualization.
6. *Dilatation:* "Once in, stay in." Replace the scalpel blade with a Trousseau dilator or curved hemostat.
7. *Insertion:* Insert a 6-mm tracheostomy (or tracheal) tube or a special cricothyroidostomy tube (Rusch, Germany).
8. *Confirmation:* Assess air and suction catheter passage through the tube. Obtain a chest radiograph, noting the tube position and the presence of any pneumothorax.
9. *Fixation:* Stabilize the tube with cloth, tracheal ties, and sutures or tape around the tube.

Emergency Aspects

The experience with emergency cricothyroidotomy suggests that adequate ventilation is achieved in most cases. Careful attention to depth and angle of penetration minimizes complications. With proper training, the procedure is easily and rapidly performed and is the emergency airway procedure of choice, especially in life-threatening airway obstruction.¹³ The clinical efficiency of cricothyroidotomy has been demonstrated particularly in trauma centers whenever a difficult intubation is encountered.

Prehospital indications for cricothyroidotomy in one large series included severe facial trauma (40%), failed oral intubation (35%), and potential cervical fracture (5%), with an 88% rate of success reported.¹⁴ When the procedure fails, the outcome usually is not good; patients in cardiac arrest demonstrated particularly poor survival or neurologic devastation.¹⁴ In another study, the most common indications for a surgical airway were oromaxillofacial trauma (67%) and failed intubation (20%). A surgical airway was required in 2% to 3% of prehospital airway emergencies; a surprisingly high success rate of 98% was reported.¹⁵

Patients have undergone cricothyroidotomy secondarily to failed intubation (e.g., resulting from emesis or hemorrhage).¹⁶ The survival rate was 32% in a reported material with significant difficulties encountered, such as misplacement of the tube (33%), insertion time longer than 3 minutes (26%), unsuccessful procedure (20%), hemorrhage (13%), and thyroid cartilage fracture (7%).¹⁶

Rapid cricothyroidotomy performed in the trauma setting allowed survival of 59% of such patients in one study.¹⁷ Minor complications occurred in 27% at subsequent conversion to conventional tracheostomy, whereas major complications were more common with immediate tracheostomy.¹⁷ Emergency cricothyroidotomy was predisposed to particularly poor outcome if instituted late in the course of respiratory failure.

Elective Utilization

The elective indications for cricothyroidotomy include the need for secretion clearance and prolonged mechanical ventilation. Because of the high risk of mediastinitis, cricothyroidostomy has been recommended instead of tracheostomy in patients after recent cardiac surgery via midline sternotomy. Cricothyroidotomy has a complication rate of 1% to 9% in patients predisposed by preceding endotracheal intubation of 7 days or more, which, therefore, is a relative contraindication.¹⁸ However, more recent clinical experience has documented that patients converted from endotracheal intubation to cricothyroidostomy after 7 days demonstrated only 5% of minimal side effects (e.g., laryngeal granulation tissue and stenosis).¹⁹

Cricothyroidostomy has also been explored for the management of secretions postoperatively with very high effi-

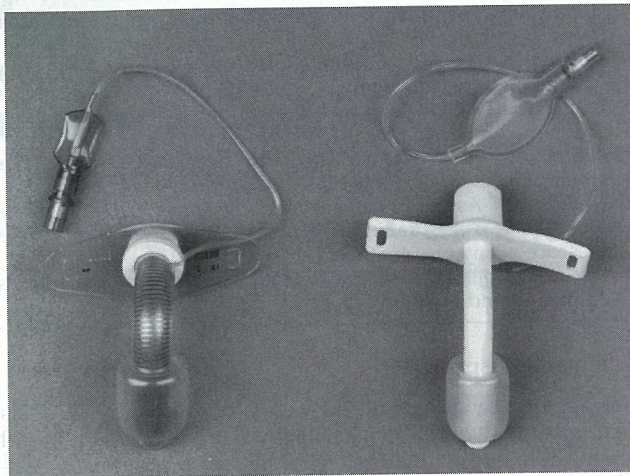


Figure 80-2. *Left*, A No. 7 cricothyroidotomy cannula. The cannula lumen is rounded at the end but ovaly shaped (6 × 8 mm ID) in the part that penetrates the cricothyroid membrane (Courtesy of Willy Rüsich, Kern-Rommelshausen, Germany). *Right*, Standard No. 6 tracheostomy tube without an inner cannula (Courtesy of Shiley Tracheostomy Products, Mallinckrodt Medical, Irvine, CA.)

cacy and a low complication rate of 3% to 8% manifested mostly as minor bleeding. Such "minitracheostomy" established through a cricothyroidotomy has an 87% success rate when maintained for approximately 10 days, enabling effective secretion removal via a narrow suction catheter.²⁰ Cricothyroidotomy and cannulation with a small adult or pediatric tracheostomy tube (Fig. 80-2) will prevent cricothyroid cartilage separation. This technique may also be used for prolonged management of mechanically ventilated patients, who preferably have been intubated for a duration shorter than 1 week and are without bleeding diathesis.

Complications

Difficulties encountered in emergency cricothyroidotomy are often related to massive neck swelling obscuring the thyroid cartilage. This emergent setting results in complications in 18% to 32% of the patients.^{16,17} These complications include hemorrhage, tube occlusion from debris, tube misplacement, and late subglottic stenosis.²¹ Tube misplacement may occur outside of the cricothyroid space in one third of such cases (e.g., into the pretracheal tissue). Unintentional passage of the tube upward into the pharynx instead of downward into the trachea may be avoided if the cricothyroidostomy tube is inserted over a guide wire, catheter, or dilating probe, which is directed to enter the trachea. Insertions through the thyroid cartilage, into the pharynx, or even intraesophageally have also been described.^{22,23}

Elective cricothyroidotomy is technically easier than tracheotomy and has only minor adverse sequelae; voice change is the most common and minimal evidence of subglottic stenosis is less common.²⁴ Patients predisposed to complications are those with cricothyroidostomy for more than 30 days, preceding intubation greater than 7 days, diagnosis of diabetes mellitus, and advanced age.^{25,26} Another strong correlate is the presence of stomal infection, causing formation of subglottic granulation tissue and subsequent cartilaginous injury and stenosis.²⁷ Thus, the procedure is associated with some morbidity manifested as moderate to severe perichondrial inflammation but only minimal stenosis. Mortality has been identified as a covariable of patients in poor condition.²⁸ Major complications have been reported

in 7% and include subglottic stenosis resulting from granulation tissue formation, whereas minor complications occurred in 30% and usually were located at the cuff site.²⁹

The most sensitive indication of dysfunction after airway intubation is temporary voice change, demonstrated in 50% to 75% of the patients.³⁰ Also, cricothyroid muscle dysfunction occurs by an unknown mechanism with normal electromyogram and muscle biopsy but manifested as diminished voice range with lower pitch.³¹ The most specific measure of iatrogenic trauma induced by cricothyroidostomy is subglottic stenosis. This problem may occur in as many as 12% of patients.^{29,30} However, most modern comparisons suggest that cricothyroidotomy performed under optimal conditions without active infection or prolonged preceding intubation has a lower rate of subglottic stenosis compared with endotracheal intubation.

PERCUTANEOUS CRICOTHYROIDOTOMY

The "cut and poke" cricothyroidotomy (using a knife blade with rubber limit followed by cannula insertion) was described by Safar and Penninckx in 1967.⁹ A "last-ditch airway" was reported in 1979, performed with a scalpel blade and insertion of an intravenous tubing spike connected to pressurized oxygen for ventilation.³² However, none of these techniques has gained significant utilization.

The first large clinical trial used the Minitrach (Portex) system consisting of a 4-mm internal diameter (ID) pediatric tube placed over an introducer through a cricothyroid membrane incision. The technique has been used in post-thoracotomy patients for up to 45 days, providing satisfactory removal by suction of retained secretions in these patients (Fig. 80-3, *left*).³³ The Minitrach II System (Portex) was re-evaluated for pulmonary toilet, demonstrating significant efficacy manifested as earlier discharge from the intensive care unit (ICU) in 88% after limited therapy (4 days). Minor bleeding in 7% was the only significant side effect.³⁴ Compared with control, this technique also demonstrated a decrease in the frequency of postoperative atelectasis, and fewer patients required bronchoalveolar lavage for secretion management.³⁵ One study, however, cited therapeutic failure in one third of its patients.³⁶

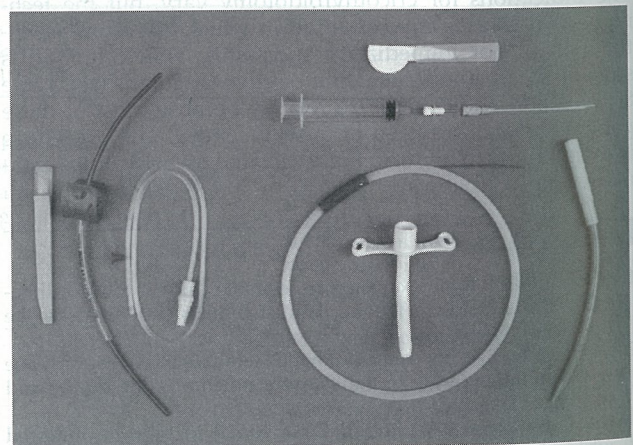


Figure 80-3. Percutaneous cricothyroidotomy kits. *Left*, The Minitrach II minitracheotomy kit, which includes a scalpel, an introducer with a 4-mm-ID cannula, and a suction catheter (Courtesy of Concord Portex, Keene, NH). *Right*, A scalpel; an 18-gauge catheter-over-needle attached to a syringe; a guide wire; a dilator; and a 6-mm-ID cannula (Courtesy of Cook Critical Care, Bloomington, IN).

The Nutrake System (International Medical Devices, Northridge, CA) has demonstrated rapid placement and high success rate after video instruction of trainees,³⁷ but the equipment is sharp, rigid, and potentially harmful. The use of minitracheostomy postoperatively in thoracic surgery patients, in whom a 20-French pediatric tracheostomy tube was placed as a cricothyroidostomy cannula for removal of retained secretions, resulted in a 99% success rate and significant decrease in the need for bronchoscopy.³⁸ Complications were minimal, with minor bleeding in a few patients. Subglottic stenosis was not demonstrated.³⁸ This procedure has minimal documented mortality but may occasionally be difficult or impossible to perform in elderly patients because of cricothyroid membrane calcification.³⁹

The Seldinger technique using a guide wire may be more amenable to use by nonsurgeons. A percutaneous method has been described in which needle placement and guide wire insertion are followed by dilatation with a nasal speculum-like dilator and placement of a 6-mm tracheostomy tube. Although cumbersome, this method suggests the use of instruments readily available to the critical care physician.³⁹ However, use of the so-called Quicktrach device resulted in longer insertion time compared with open technique and a complication rate of up to 27% related to the operator's level of experience.⁴⁰

The Melker percutaneous dilatational cricothyroidotomy kit (Cook, Bloomington, IN) allows cricothyroid membrane needle puncture, guide wire placement, and insertion of a unitized, anatomically conformed tube and dilator in a single step, minimizing the risk of malposition and cartilage damage (Fig. 80-3, right). This appears to be a safe and effective technique. Prior devices have been difficult to insert, often resulting in paratracheal cannula placement and subcutaneous emphysema.⁴¹ Correct position is verified by fiberoptic bronchoscopy, but suction catheter passage, unobstructed airflow, or normal end-tidal carbon dioxide concentration may suffice.⁴¹

Percutaneous cricothyroidotomy, as described previously, allows placement of a definitive airway in the routine or emergency setting by practitioners of all specialties. However, some available kits provide dangerously traumatic equipment. The procedure may also lead to significant complications in patients with anatomic distortion and bleeding diathesis or when placed by an inexperienced operator. Therefore, the technique should be included in the educational airway repertoire of all critical care medicine physician trainees.

SURGICAL TRACHEOTOMY

Historic Background

Although tracheotomy was a procedure practiced already in ancient Egypt, little is known about the technique used. However, Vesalius in 1555 published a compendium illustrating a tracheotomy performed by cherubs on a cow, hinting at potential complications of the procedure itself. His description of performing a tracheotomy reads "but that life may in a manner of speaking be restored to the animal, an opening must be attempted in the trunk of the trachea into which a reed or cane should be put; you will then blow into this so that the lung may rise again and the animal takes in air."⁴²

Use of the tracheotomy procedure resurfaced during the diphtheria epidemic of the 19th century. Trousseau described its use to prevent asphyxia and airway obstruction. Jackson, in his classic publication of 1921, discussed how poor tracheotomy technique caused laryngeal stenosis, specifically with a hasty operation; general anesthesia; "high tracheotomy"; cricoid cartilage division; tight wound suture

closure; poor postoperative care; cannula of improper size, shape, or material; and neglect of ordering decent cleanliness in weaning from the cannula.⁴¹ The best described complication in diphtheria survivors is subglottic stenosis. "The difficulties and dangers, experienced in so many cases on attempting after the pulmonary disease had subsided, removal of the cannula [sic] from the trachea in which it has remained for some time, is well known in many. Chief among these are the sudden attacks of asphyxia, which occur at this period."⁴³

Indications

The indications for tracheostomy are diverse. The only contraindication is the necessity for an emergency airway because this procedure is time consuming and requires significant expertise. Comparison of emergent versus elective tracheotomy reveals a twofold complication rate with the former because of longer time spent isolating the trachea as a result of commonly occurring bleeding.⁴⁴ The procedure requires attention to detail and is truly an operative intervention that preferably should be performed in the operating suite and be followed by intensive care, if conditions so warrant.

PROCEDURE

1. *Setting:* An operative suite is preferred.
2. *Position:* The head and neck are extended, using a towel roll beneath the shoulders but with the head still resting against the operating table.
3. *Anesthesia:* General anesthesia is preferred with preceding orotracheal or nasotracheal intubation.
4. *Skin incision:* A transverse incision is made 1 to 2 cm below the cricoid cartilage in the triangle formed by the medial sternocleidomastoid heads and cricoid cartilage.
5. *Dissection:* Dissection must be adequate to identify fascial planes. Strap muscles in the midline are separated.
6. *Laryngeal nerves:* Avoid lateral tracheal dissection, which may cause injury to the recurrent laryngeal nerves.
7. *Thyroid isthmus:* Transect with suture ligature. If this area is not divided, occlusion can occur at accidental decannulation.
8. *Tracheal incision:* A tracheal incision is done at the second to third or third to fourth tracheal cartilage. Midline division (not the horizontal stab method) is used.
9. *Tracheal resection:* A tracheal fenestration wider than 5 mm should be avoided. A wide vertical flap or excessively large tracheal window causes risk of stenosis formation after decannulation.
10. *Stabilization:* Skin hooks (or Allis Clamp) superiorly and inferiorly are used.
11. *Tracheal stoma:* If a tracheal stoma is used, suture the inverted tracheal flap to the subcutaneous tissue. Use lateral tracheal stay sutures, exteriorized, and taped to skin.
12. *Cannulation:* The tube is 50% to 75% of the diameter of the trachea. Insert the tube at a right lateral angle and rotate caudad. The sizing is as follows: males, 7- to 8-mm ID; females, 6- to 7-mm ID.
13. *Confirmation:* Correct position of tracheostomy tube is confirmed by free airflow, suction catheter passage, or radiography.
14. *Fixation:* Tracheal sutures are placed for identification of stoma in case of early tube dislocation, and around-the-neck straps are placed for fixation.
15. *Incision closure:* The skin is loosely approximated to prevent subcutaneous emphysema.

Technique

Tracheostomy success and complications are dependent on surgical technique and the equipment used. If an inverted horseshoe flap technique is used, the flap is sutured to the subcutaneous tissue. This technique was designed by Bjork

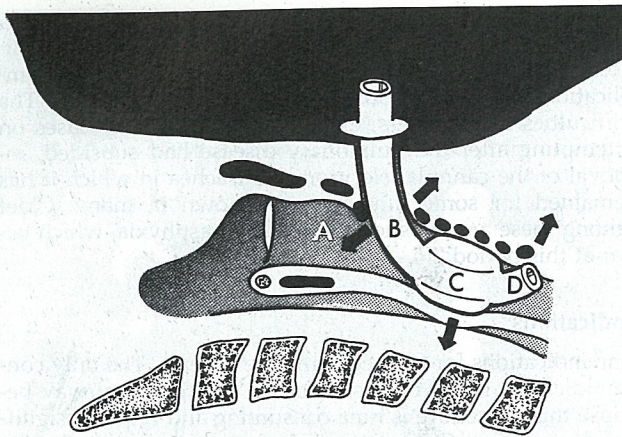


Figure 80-4. Schematic illustration of tracheostomy-induced lesions. A = Too high area for tube position; B = stoma damage area; C = cuff pressure-induced lesion; D = anterior lesion caused by the tube tip.

and Engstrom to avoid pretracheal insertion after early dislocation of the tracheostomy tube.⁴⁵ The oval tracheal window with a diameter of one half of the tracheal width has been suggested for optimal tube placement.⁴⁶ However, resection of less than 5-mm width is sufficient for reinsertion of an accidentally dislodged tracheostomy tube. The different methods compared clinically in a pediatric model suggest that the lowest rate of stenosis occurs with the vertical tracheal incision followed by the horizontal H technique, and the most significant rate of stenosis occurs with the inverted-U flap.⁴⁷

The design characteristics of the tracheostomy tube are also important. Pressure necrosis occurring between the posterior tracheal wall and vertical body of the tube at the thoracic inlet may be minimized by tube shape (i.e., modification of length and curvature) as well as stable tube fixation (Fig. 80-4).⁴⁸ Longer tracheostomy tubes may impact against the carina or result in a right mainstem bronchus intubation.⁴⁹ Thus, the tracheostomy tube should be soft but resilient and straight in the intratracheal position, resist torque, and be of appropriate length (Table 80-2, Fig. 80-5).

For the spontaneously breathing patient, the fenestrated tube allows use of the larynx for speech and better respiratory toilet. However, position of the fenestration is crucial to avoid obstruction. Individualizing its placement and using tubes with multiple small openings compared with one large fenestration are advantageous techniques (Fig. 80-6).⁵⁰

The ideal tracheostomy cuff should have a sufficiently large sealing surface area and be of the large-diameter, high-volume, low-pressure variety.⁵¹ Prevention of cuff complications is best addressed by cuff inflation to a maximum of

TABLE 80-2. Tracheostomy Tube Size

| Tracheostomy Tube Size (French) | Inner Diameter (mm) | Outer Diameter (mm) |
|---------------------------------|---------------------|---------------------|
| 5 | 5.0 | 7.0-8.5 |
| 6 | 6.0 | 8.1-9.9 |
| 7 | 7.0 | 9.6-11.3 |
| 8 | 8.0 | 10.9-12.6 |
| 9 | 9.0 | 12.1-14.0 |
| 10 | 10.0 | 13.3-13.5 |

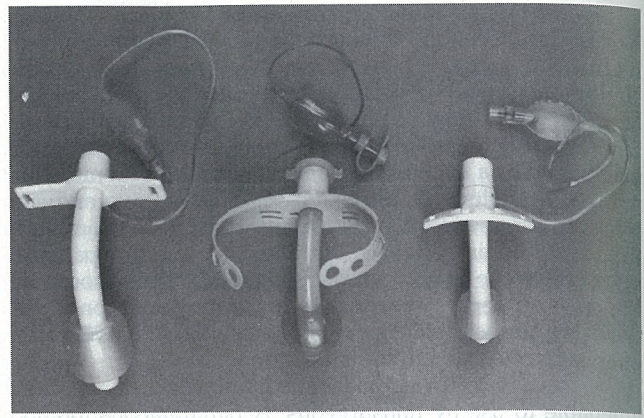


Figure 80-5. Tracheostomy tubes. *Left*, Soft tube without inner cannula (Courtesy of Shiley Tracheostomy Products, Mallinckrodt Medical, Irvine, CA). *Middle*, Soft tube without inner cannula (Courtesy of Concord Portex, Keene, NH). *Right*, Rigid tube with inner cannula (Courtesy of Shiley Tracheostomy Products, Mallinckrodt Medical, Irvine, CA).

25 cm H₂O pressure and frequent monitoring unless preset automatic cuff pressure technique is used (Fig. 80-7).

Emergency Versus Elective Tracheotomy

The emergency indications for tracheostomy are few but occur when endotracheal intubation is impossible and cricothyroidotomy is precluded by high-grade upper airway obstruction, massive neck swelling, or laryngeal injury. When those conditions are encountered, a finder needle on a saline-filled syringe is helpful in locating the trachea.

Tracheostomy has a high associated morbidity and significant mortality from different complications occurring after prolonged intubation.⁵² However, the mortality of ICU patients caused by underlying disease must be separated from that caused by the procedure itself.⁶

Tracheostomy complications such as bleeding or pneumothorax usually present early (i.e., during tracheotomy or within 2 days). Tracheobronchopulmonary infections occur late and with high frequency in critically ill patients.⁵³ The tracheotomy procedure has been performed safely at the

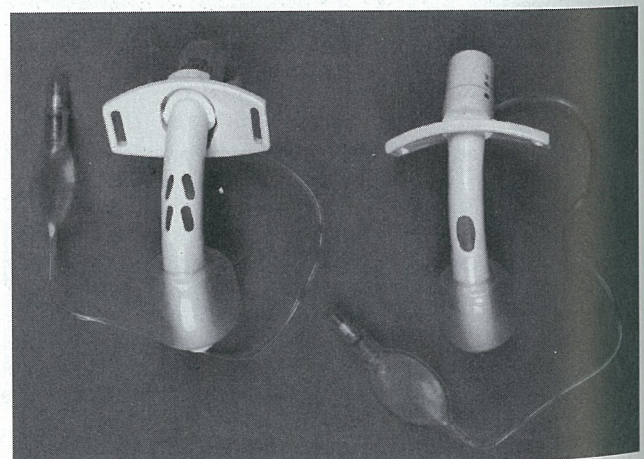


Figure 80-6. Fenestrated tracheostomy tubes. *Left*, Multiple fenestrations (Courtesy of Shiley Tracheostomy Products, Mallinckrodt Medical, Irvine, CA). *Right*, Single fenestration (Courtesy of Shiley Tracheostomy Products, Mallinckrodt Medical, Irvine, CA).

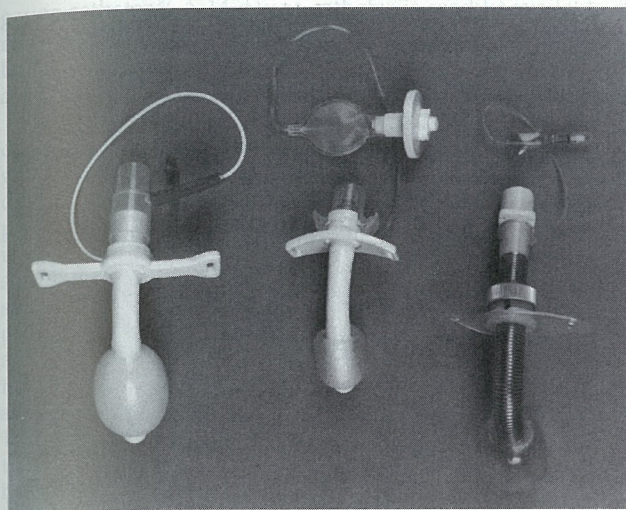


Figure 80-7. Modified tracheostomy cannulas. *Left*, Foam cuff tube (Courtesy of Bivona, Gary, IN). *Middle*, Tube with a cuff regulating device (Courtesy of Shiley Tracheostomy Products, Mallinckrodt Medical, Irvine, CA). *Right*, Tube allowing variable length of insertion (Courtesy of Willy Rüsck, Kernen-Rommelshausen, Germany).

bedside in selected patients under local anesthesia and intravenous sedation without significant complications, avoiding the risk of operating room transfer.⁵⁴ Timing strategies for tracheotomy are numerous and should be individualized. One clinical trial examined tracheotomy performed in burn patients on day 1 (7%), day 8 (17%), and day 14 (58%), with the tracheostomy maintained for 1 to 208 days without clear correlation to complications.⁵⁵ Tracheostomy within 4 days has been recommended in trauma patients, resulting in a decreased mechanical ventilation requirement and improved pulmonary toilet with less airway and pulmonary infections.⁵⁶ Similarly, early tracheostomy (within 7 days) has proven superior based on a shorter period of mechanical ventilation and length of ICU and hospital stay.⁵⁷ However, another study of trauma patients showed no difference in laryngotracheal complications between early (fewer than 2 weeks) and late (more than 2 weeks) tracheostomy.⁵⁸

Current recommendations are based on clinical evaluation. There are isolated data to suggest that nasal intubation is equivalent to tracheostomy in the incidence and onset of laryngeal complications.⁵⁹ Tracheostomy may be superior to translaryngeal tracheal intubation in specific patient populations, such as those with burns, who have an increased incidence of laryngotracheal granuloma formation and stenosis.⁶⁰ The preponderance of evidence suggests that tracheostomy (14%) is associated with less laryngeal trauma than nasotracheal or orotracheal intubation (57%).⁶¹ Patients also find tracheostomy more comfortable, and it allows them to communicate. It simplifies airway nursing care, and in one study 92% of the patients preferred this technique for artificial airway requirements of more than 10 days.⁶¹

Complications

Most initial perioperative tracheostomy complications are minor, including hemorrhage and subcutaneous emphysema. Major early complications such as loss of airway control, obstruction, or excessive blood loss are uncommon. Mediastinal emphysema and/or unilateral or bilateral pneumothoraces may suddenly develop if the patient has an occluded airway during the procedure and is struggling

to breathe. When the pretracheal fascia is transected, the excessive negative intrapleural pressure may create a pressure gradient large enough to rupture the pleura with air entering the pleural cavity from the outside. Whenever possible, tracheotomy should be performed with preceding tracheal intubation. The reported overall complication rate of tracheostomy varies between 6% and 48%, which is still less than that encountered with prolonged endotracheal intubation.^{58, 62, 63}

The most often discussed complication is tracheostenosis. The most significant lesions are found at the cuff site, where high tracheal wall pressure may cause circumferential ulceration, ischemic necrosis, and subsequent scarring.⁶⁴ The incidence of this complication has decreased from 6% in the 19th century to between 1% and 2% today.^{6, 43, 62} These lesions are mainly caused by a cuff pressure that is too high with a distinct pathogenesis and outcome. However, removal of too much of the tracheal wall and excessive movement of the tracheostomy tube may also cause stenosis at the stoma level.

The most common complication is infection with far-reaching sequelae (Table 80-3). Those with tracheostomy have a higher rate of lower respiratory tract colonization (76%) with gram-negative rods, such as *Pseudomonas aeruginosa*, often causing tracheobronchitis.⁶⁵ The bacteria that colonize the respiratory tree at the time of tracheostomy subsequently may grow in number and pathogenic properties.⁶⁶ More severe infections include necrotizing tracheitis associated with purulent stomal drainage and difficult mechanical ventilation caused by air leak and peristomal cavitation.⁶⁷ Critically ill patients are predisposed to these complications, if colonized with *Pseudomonas*, *Enterobacter*, or *Klebsiella*.⁶⁷ Paratracheal mediastinal abscess formation has been described as being associated with upper lobe consolidation and septicemia.⁶⁸ Tracheal soft-tissue injury is usually localized to the posterior wall (e.g., in cases of mucosal rigidity associated with radiation therapy or infection).⁶⁷ Massive dissecting emphysema can occur when the tracheostomy tube is malpositioned into the pretracheal space with positive-pressure ventilation applied.⁶⁹

Life-threatening hemorrhage involving the brachiocephalic trunk (innominate artery) and resulting from tube tip or cuff erosion,⁷⁰ has been found in 1% of patients. It occurs especially with cuff overdilatation, low-lying tracheostomy, or pretracheal soft-tissue infection.^{70, 71} Acute hemostasis is achieved by cuff hyperinflation and pretracheal digital compression of the innominate artery, followed by emergency exploration for brachiocephalic trunk division and suture ligation, which, when successful, is associated with good neurologic outcome.⁷¹

Vascular erosion may also present as a fistula. An innominate artery fistula may be caused by the extratracheal portion of the tracheostomy tube, whereas the intratracheal fis-

TABLE 80-3. Complications Associated with Tracheostomy* (In Approximate Order of Frequency)

| | |
|------------------------|------------------------------------|
| Pneumonia | Mediastinal emphysema |
| Tracheobronchitis | Tracheal-innominate artery fistula |
| Hemorrhage | Necrotizing tracheitis |
| Stomal infection | Paratracheal abscess |
| Tracheostenosis | Posterior wall laceration |
| Tracheomalacia | Tracheoesophageal fistula |
| Subcutaneous emphysema | |

*For details see Holley and Jordan,⁴ Minard et al,⁶ Boyd and Benzel,⁶² Miller and Kapp,⁶³ Snow et al,⁶⁷ Cole and Kerr,⁶⁸ Arola et al,⁷⁶ Adolfsson et al,⁷¹ Takano et al,⁷² Schachner et al.¹⁰⁸

tula is caused by the tube tip or cuff.⁷² Patients are predisposed by low-lying tracheostomy (below the fourth tracheal cartilage), high innominate artery position, infection, and steroid use.⁷² Thus, an extratracheal innominate artery fistula may present with exsanguination and hemodynamic instability, whereas a tracheoinnominate fistula may present with less bleeding (100–150 mL) but instead life-threatening airway obstruction and asphyxia.⁷³

Tracheoesophageal fistula occasionally occurs secondary to compression between an overdistended cuff or the posterior convex contour of a curved rigid tracheostomy tube and nasogastric tube.⁷⁴ This complication occurs late in patients with poor prognosis, is difficult to treat, and is usually lethal.⁷⁵

The institution of a tracheostomy requires constant vigilance and frequent assessment of complications. Prospective laryngotracheal examination has demonstrated asymptomatic stomal narrowing in 16%, bleeding in 10%, and miscellaneous problems in an additional 17%. Sellery and colleagues reported tracheostenosis severe enough to require tracheal resection in 8% of patients.⁷⁶ Follow-up of such patients should include routine bronchoscopic surveillance.⁷⁶ Video technique is especially helpful in the diagnosis of phonation difficulty and aspiration problems, which are often caused by laryngeal nerve or vocal cord dysfunction.⁷⁷ Conventional tomography of the larynx has been replaced by computed tomography in the diagnosis of glottic abnormalities.⁷⁷ The need for therapeutic intervention of subglottic stenosis may be related to the higher likelihood of survival with current resuscitation techniques.⁷⁸ Patients are predisposed for tracheostomy complications by abnormal neck anatomy or low-lying tracheostomy.⁷⁹

Medical therapy includes the use of topical and systemic antibiotics because stenosis is related to an acute inflammatory and infectious phase.⁸⁰ The use of systemic corticosteroids has been explored to address the reactive scarring phase.⁸¹ Progressive balloon dilatation has been described initially in this condition.⁸² Surgical repair is required for patients with tracheal diameter narrowing of greater than 50%.⁸³ Laryngostenosis occurs most commonly at the cricoid cartilage level, the narrowest part of the upper airway.⁸⁴ Tracheostenosis results from endotracheal trauma most often because of a cuff pressure that is too high. As previously indicated, the surgical approach includes primary resection with end-to-end anastomosis⁷⁵ or multistage endoscopic laser resection.⁷⁸

PERCUTANEOUS TRANSTRACHEAL CATHETERIZATION

Historic Background

Transtracheal artificial ventilation was described by Reed and colleagues in 1954 in a canine model using a tapered 13-gauge steel needle and a flow system of 15 L per minute for 30 minutes.⁸⁵ This technique allowed adequate oxygenation but inadequate ventilation, with increasing hypercarbia and resultant respiratory acidosis causing hemodynamic depression with decreasing mean arterial pressure and heart rate and increasing central venous pressure.⁸⁵ Therefore, the pressure-flow characteristics of resuscitation needles were analyzed. The 13-gauge needle with 88 cm H₂O pressure was found to permit 200 mL/s of gas flow.⁸⁶ However, the normal adult at rest has a peak inspiratory flow of about 400 mL/s. Therefore, the described system was capable of maintaining adequate ventilation in an apneic model only for a few minutes.⁸⁶ This method was further explored, and the authors concluded that 18-gauge and 16-gauge catheters

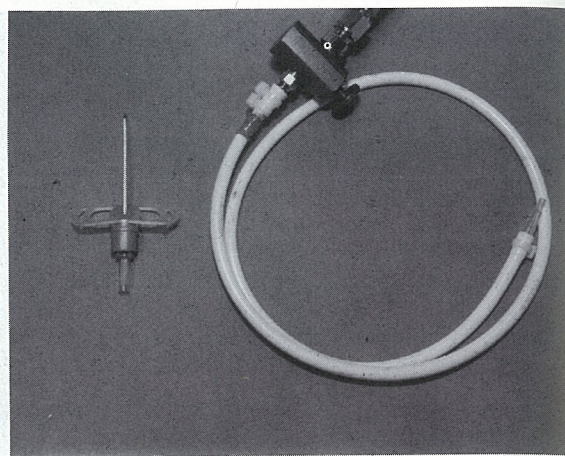


Figure 80-8. Left, Cricothyroidotomy catheter device with wings (for fixation) mounted onto a needle for insertion (Courtesy of CVM Medizintechnik, Sulz/Neckar, Germany). Right, Manual activation jet ventilation system designed to provide a pressure of 50 psi. The system is suitable for ventilation with the catheter to the left.

are too narrow as emergency airways, with survival limited to 5 to 15 minutes.⁵ The 13-gauge system allowed survival up to 60 minutes in dogs, but in calves survival was limited to 16 minutes.⁵ A cannula size of 13 to 14 gauge necessitates a high-pressure (40–50 psi) jet insufflation system for adequate ventilation (Fig. 80-8).

PROCEDURE

Percutaneous transtracheal catheterization is indicated for failed intubation as the procedure of choice in partial airway obstruction, but success depends on operator experience. There are some contraindications to the procedure, including operator inexperience, severe coagulopathy, and complete airway obstruction (e.g., caused by laryngeal trauma), with possibilities for inadequate exhalation (see Table 80-1).

1. *Position:* Extend the neck (if there is no cervical spine trauma) with the face directed straight anteriorly (not turned to the side).
2. *Stabilization:* The nondominant hand holds thyroid cartilage.
3. *Palpation:* The index finger guides to cricoid cartilage.
4. *Apparatus:* Use a saline-filled syringe, catheter-over-needle assembly, connector, and oxygen source (50 psi).
5. *Entry:* The catheter/syringe is directed 45° caudad and inserted cautiously into the upper trachea while avoiding lesions of the posterior tracheal wall. A free airflow indicates correct position.
6. *Connection:* Withdraw the needle, and connect the tubing from the oxygen source (50 psi).
7. *Ventilation:* An inspiration-expiration ratio of 1:4 to prevent air trapping is used.
8. *Stabilization:* Always retain control of the catheter until it is permanently secured in the neck.
9. *Monitoring:* Look for indications of barotrauma, such as hypotension or subcutaneous emphysema.
10. *Confirmation:* Chest radiograph should be taken to check for catheter position and absence of pneumothorax and/or subcutaneous air.

Mechanics

The most critical issue regarding efficacy of ventilation is the diameter of the catheter, where turbulent flow varies inversely with the radius to the fourth power according to the law of Poiseuille. The minimum catheter size should be 14 gauge, which permits a flow 10 times greater than a 22-

gauge catheter.⁸⁷ A 14-gauge catheter is readily available in most hospitals. However, it is too narrow for passive exhalation, which must take place through the patient's natural airway.

The flow delivery system is next in importance when determining ventilatory efficacy. The minimum pressure gradient required to generate flow through a small-diameter cannula is 0.1 to 0.5 psi (7–35 cm H₂O).⁸⁸ However, the pressure gradient required to achieve adequate ventilation is far greater, easily provided by a 50-psi (3500 cm H₂O) source, but not by a manual bag-valve or demand-valve system generating a pressure of less than 60 cm H₂O.⁸⁷ The previously described model with a 14-gauge cannula using a 50-psi jet system instead of manual bagging provided a flow five times greater (235–1034 mL/s) (i.e., enough to achieve adequate ventilation).⁸⁷ The lower flow systems of 15 L/min may provide adequate oxygenation, but ventilation is inadequate and survival is limited to 1 to 2 hours before lethal hypercarbia and respiratory acidosis occur.^{89,90}

The percutaneous transtracheal ventilation (PTV) system has been described as a life-support adjunct in 80 patients treated at the accident site.⁹¹ Using PTV, a canine hemorrhagic shock model demonstrated adequate oxygenation and ventilation (partial pressure of carbon dioxide of 21 mm Hg) but still serious metabolic acidosis (pH 7.14).⁹²

The indications for emergency use include the presence of partial airway obstruction. If this obstruction is due to a laryngotracheal foreign body, PTV may assist in expelling the object.⁹³ However, complete airway obstruction does not provide for adequate exhalation, resulting in air trapping and hyperinflation. In such cases, barotrauma becomes a concern, with the possibility of bilateral tension pneumothorax, cardiac arrest, and death.

Emergency percutaneous transtracheal catheterization has been used for treatment of airway obstruction with reasonable success, but complications including catheter displacement, total expiratory obstruction, and barotrauma were encountered.⁹⁴ Used cautiously, this technique has been explored for difficult intubation with no adverse effects on morbidity or mortality.⁹⁵ The technique has proven effective in providing more adequate oxygenation than ventilation.⁹⁶ Clinical evaluation using a commercially available emergency infusion device (Arrow International, Reading, PA), with an 8.5-gauge catheter resulted in adequate ventilation in partial-obstruction models.⁹⁷ A 13-gauge angulated catheter with side holes placed between the tracheal cartilages has also been used successfully in patients.⁹⁸ Further, the Minitrach II System (Portex) has been adapted for jet ventilation, proving efficacious in patients.⁹⁹

Complications

High-frequency jet ventilation (HFJV) at a rate of 250 to 400 per minute has been provided via transtracheal catheters, but airway inflammation occurs in all such cases and is manifested as mucosal erosion and leukocyte infiltration at the catheter tip. This HFJV injury is greater than with conventional intubation and high-frequency ventilation at a lower rate (150/min) as well as traditional ventilation frequency (20/min).¹⁰⁰ Tracheal mucosal hemorrhage may occur secondary to catheter trauma. Posterior tracheal wall perforation has also been reported.¹⁰⁰

Cardiac sequelae are related to the presence of air trapping often caused by auto-positive end-expiratory pressure (PEEP) resulting from obstructed exhalation. Increasing PEEP is productive to a point with increased peak airway and mean arterial pressures, improved oxygenation, and

reduced shunt fraction.¹⁰¹ However, at levels greater than 20 cm H₂O, this auto-PEEP also becomes a limiting factor, decreasing cardiac output and increasing intracranial pressure.¹⁰¹ The hypovolemic patient, in particular, will improve when switched to low-frequency ventilation.¹⁰²

The pulmonary complications of PTV include barotrauma manifested as unilateral or bilateral pneumothorax, pneumomediastinum, and subcutaneous emphysema.^{103,104} This interstitial emphysema may also dissect along the great vessels and secondarily rupture into the abdominal cavity, forming pneumoperitoneum,¹⁰⁵ which has led to unnecessary laparotomy because of suspected gastrointestinal perforation.

PERCUTANEOUS DILATATIONAL TRACHEOSTOMY

Historic Background

Percutaneous tracheostomy using a large-bore needle and guide wire was described in 1976 for emergency use.¹⁰⁶ Current discussion centers on the use of this technique in the ICU at the bedside. This percutaneous tracheostomy technique has been used for treatment of excess secretions, in patients with prolonged intubation for mechanical ventilation, and in patients with neurologic dysfunction. It has been performed electively (77%), urgently (28%), or as an occasional emergency procedure (5%).¹⁰⁷ This technique proved successful in 90% of patients when performed in the emergency department and in 70% of those done in the ICU or operating room, all with minimal morbidity.¹⁰⁷

PROCEDURE

1. *Position:* The neck is hyperextended.
2. *Anesthesia:* Local anesthesia is preferable.
3. *Landmarks:* A minimal horizontal incision is made midway between the cricothyroid membrane and the sternal notch.
4. *Puncture:* Intercartilag membrane is punctured at a 45° caudad angle, avoiding the posterior tracheal wall.
5. *Aspiration:* Intratracheal position is confirmed by aspiration of air into a saline-filled syringe.
6. *Catheter:* Advance the catheter over the needle with air aspiration reconfirmation.
7. *Guide wire:* The wire is inserted and the catheter removed.
8. *Dilatation:* Progressively larger dilators are passed.
9. *Tracheostomy tube:* The tube is passed over the largest dilator, which is subsequently removed.
10. *Confirmation:* Position is confirmed by air entry and suction catheter passage.
11. *Stabilization:* Around-the-neck straps are placed for fixation.

Equipment

The described procedure is simplified by use of a commercially available kit (Fig. 80–9; Cook, Bloomington, IN). The technique is safe but relatively slow. Modifications for rapid placement include the Rapitrach System (Premier Medical, Norristown, PA), which uses a hinged device as a dilator for effective placement^{108,109} of the tracheostomy tube. The Nutrach System (International Medical Device, Northridge CA) includes a steel cannula that has been used for both cricothyroidostomy and tracheostomy. The original progressive dilator technique was described by Ciaglia and colleagues in 1985 and stressed entry between the cricoid cartilage and first tracheal cartilage to reduce the incidence and severity of complications.¹¹⁰ A clinical trial comparing the Rapitrach and Cook devices with conventional tracheostomy demonstrated procedure times of 5, 15, and 60 minutes, respectively (see Fig. 80–9).¹¹¹ However, the highest complication rate was found with the Rapitrach System.¹⁰⁹

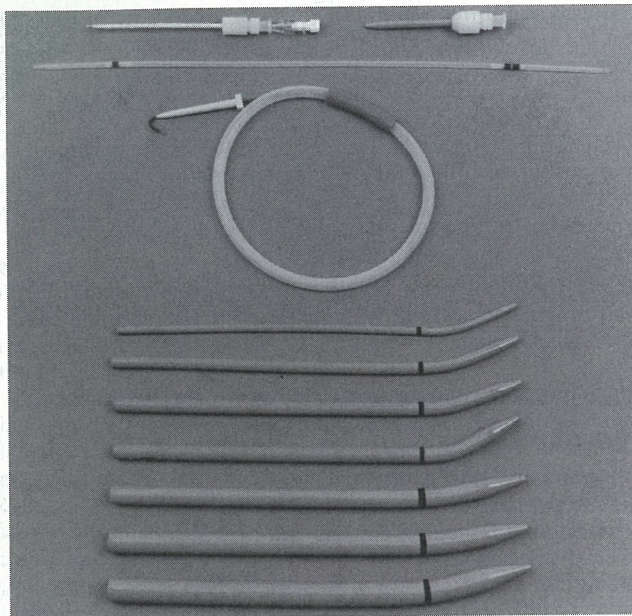


Figure 80-9. Percutaneous dilational tracheostomy kit (Courtesy of Cook Critical Care, Bloomington, IN). From top to bottom: *Step 1:* A catheter-over-needle is used to puncture the trachea. *Step 2:* After needle removal, a plastic guide is inserted through the catheter. *Step 3:* The catheter is removed, and a guide introducer is inserted over the plastic guide, which is replaced by a guide wire. *Step 4:* The introducer is removed, and progressively larger dilators are inserted; finally, a tracheostomy cannula is inserted over the dilator.

The Cook device offered an appropriate compromise in the rapidity of the technique and complication rate.

Complications

The complication rate of this dilatational tracheostomy technique is minimal, and the mortality has been reported at only 1%.^{107, 112, 113} This low complication rate of the dilatational technique (mainly hemorrhage) compares favorably with the standard procedure, in which obstruction, hemorrhage, pneumothorax, and wound infection occur frequently.⁸¹ However, occasional cases of life-threatening hemorrhage as well as pneumothorax have also been reported with the percutaneous technique.¹¹⁴ Tomography confirms the advantage of percutaneous versus open tracheostomy with a lower frequency of overall complications using the former technique.¹¹⁵ The incidence of complications may be minimized by endoscopic guidance of the percutaneous technique confirming intratracheal placement and, if necessary, guiding insertion of the tracheostomy tube.¹¹⁶ However, such endoscopy is not a practical choice in emergency situations.

CONCLUDING REMARKS

The success of the percutaneous cricothyroidostomy and tracheostomy techniques includes appropriate patient selection. There is a reported failure rate of 22% in percutaneous tracheostomy of patients with "non-ideal anatomy."¹¹⁷ The best of circumstances allows the percutaneous cricothyroidostomy procedure to be performed in 30 seconds instead of several minutes for a tracheostomy.¹¹² The percutaneous dilatational tracheostomy procedure is slow but has a 94%

success rate, although the failure rate has been cited to be higher when performed by nonexperienced operators.¹¹⁸ However, the postoperative result has been optimal (95%) with decannulation possible in most patients.¹¹³

References

1. Redan JA, Livingston DH, Tortella BJ, et al: The value of intubating and paralyzing patients with suspected head injury in the emergency department. *J Trauma* 1991; 31:371.
2. Murphy-Macabobby M, Marshall WJ, Schneider C, et al: Neuromuscular blockade in aeromedical airway management. *Ann Emerg Med* 1992; 21:664.
3. Suderman VS, Crosby ET, Lui A: Elective oral tracheal intubation in cervical spine-injured adults. *Can J Anaesth* 1991; 38:785.
4. Holley J, Jordan R: Airway management in patients with unstable cervical spine fractures. *Ann Emerg Med* 1989; 18:1237.
5. Hughes RK: Needle tracheostomy. *Arch Surg* 1966; 93:834.
6. Minard G, Kudsk KA, Croce MA: Laryngotracheal trauma. *Am Surg* 1992; 58:181.
7. Steinert R, Lullwit E: Failed intubation with case reports. *HNO* 1987; 35:439.
8. Goldberg J, Levy PS, Morkovin V, et al: Mortality from traumatic injuries: A case-control study using data from the National Hospital Discharge survey. *Med Care* 1983; 21:692.
9. Safar P, Penninckx J: Cricothyroid membrane puncture with special cannula. *Anesthesiology* 1967; 28:943.
10. Caparosa RJ, Zabatsky AR: Practical aspects of the cricothyroid space. *Laryngoscope* 1959; 67:577.
11. Jackson C: High tracheotomy and other errors: The chief causes of chronic laryngeal stenosis. *Surg Gynecol Obstet* 1921; 32:392.
12. Brantigan CO, Grow JB Sr: Cricothyroidotomy: Elective use in respirator problems requiring tracheotomy. *J Thorac Cardiovasc Surg* 1976; 71:72.
13. Plummer WB: The cricothyroidotomy: A lifesaving adjunct in acute obstructive asphyxia. *J Georgia Dent Assoc* 1969; 43:8.
14. Spaite DW, Joseph M: Prehospital cricothyrotomy: An investigation of indications, technique, complications, and patient outcome. *Ann Emerg Med* 1990; 19:279.
15. Boyle MF, Hatton D, Sheets C: Surgical cricothyrotomy performed by air ambulance flight nurses: A 5-year experience. *J Emerg Med* 1993; 11:41.
16. McGill J, Clinton JE, Ruiz E: Cricothyrotomy in the emergency department. *Ann Emerg Med* 1982; 11:361.
17. DeLaurier GA, Hawkins ML, Treat RC, et al: Acute airway management: Role of cricothyroidotomy. *Am Surg* 1990; 56:12.
18. Boyd AD, Romita MC, Conlan AA, et al: A clinical evaluation of cricothyroidotomy. *Surg Gynecol Obstet* 1979; 149:365.
19. O'Connor JV, Reddy K, Ergin MA, et al: Cricothyroidotomy for prolonged ventilatory support after cardiac operations. *Ann Thorac Surg* 1985; 39:353.
20. Pedersen J, Schurizek BA, Melsen NC, et al: Minitracheotomy in the treatment of postoperative sputum retention and atelectasis. *Acta Anaesthesiol Scand* 1988; 32:426.
21. Nugent WL, Rhee KJ, Wisner DH: Can nurses perform surgical cricothyrotomy with acceptable success and complication rates? *Ann Emerg Med* 1991; 20:367.
22. Slobodkin D, Topliff S, Raife JH: Retrograde intubation of the pharynx: An unusual complication of emergency cricothyrotomy. *Ann Emerg Med* 1992; 21:220.
23. Ryan DW, Dark JH, Misra U, et al: Intraesophageal placement of minitracheotomy tube. *Intensive Care Med* 1989; 15:538.
24. Holst M, Hedenstierna G, Kumlien JA, et al: Five years experience of coniotomy. *Intensive Care Med* 1985; 11:202.
25. Kuriloff DB, Setzen M, Portnoy W: Laryngotracheal injury following cricothyroidotomy. *Laryngoscope* 1989; 92:125.
26. Weymuller EA Jr, Cummings CW: Cricothyroidotomy: The impact of antecedent endotracheal intubation. *Ann Otol Rhin Laryngol* 1982; 91:437.
27. Holst M, Veress B: The healing of cricothyroidostomy in pigs: A morphological study. *Acta Otolaryngol* 1989; 107:300.
28. Greisz H, Qvarnstorm O, Willien R: Elective cricothyroidotomy: A clinical and histopathological study. *Crit Care Med* 1982; 10:387.

29. Sise MJ, Shackford SR, Cruickshank JC: Cricothyroidotomy for long-term tracheal access: A prospective analysis of morbidity and mortality in 76 patients. *Ann Surg* 1984; 200:13.
30. Gleeson MJ, Pearson RC, Armistead S, et al: Voice changes following cricothyroidotomy. *J Laryngol Otol* 1984; 98:1015.
31. Holst M, Halbig I, Persson A, et al: The cricothyroid muscle after cricothyroidotomy: A porcine experimental study. *Acta Otolaryngol* 1989; 107:136.
32. Fisher JA: A "last ditch" airway. *Can Anaesth Soc J* 1979; 25:225.
33. Matthews HR, Hopkinson RB: Treatment of sputum retention by minitracheotomy. *Br J Surg* 1984; 71:147.
34. Mastboom WJB, Wobbes TH, van den Dries A: Bronchial suction by minitracheotomy as an effective measure against sputum retention. *Surg Gynecol Obstet* 1991; 173:187.
35. Randell TT, Tierala EK, Lepantalo MJ, et al: Prophylactic minitracheostomy after thoracotomy: A prospective, random control, clinical trial. *Eur J Surg* 1991; 157:501.
36. Clancy MJ: A study of the performance of cricothyroidotomy on cadavers using the Minitrach II. *Arch Emerg Med* 1989; 6:143.
37. Ravlo O, Bach V, Lybecker H, et al: A comparison between two emergency cricothyroidotomy instruments. *Acta Anaesthesiol Scand* 1987; 31:317.
38. Au J, Walker WS, Inglis D: Percutaneous cricothyroidostomy (minitracheostomy) for bronchial toilet: Results of therapeutic and prophylactic use. *Ann Thorac Surg* 1989; 48:850.
39. Ciaglia P, Brady C, Graniero D: Emergency percutaneous dilatational cricothyroidostomy: Use of modified nasal speculum. *Am J Emerg Med* 1992; 10:152.
40. Frei FJ, Meier PY, Lang FJ, et al: Cricothyrotomy using the Quicktrach coniotomy instrument set. *Anasth Intensivther Notfallmed* 1990; 25(Suppl 1):44.
41. Randell T, Kalli I, Lindgren L, et al: Minitracheotomy: Complications and follow-up with fiberoptic tracheoscopy. *Anaesthesia* 1990; 45:875.
42. Vesalius A: *DeHumani Corporis Fabrica Libri Septem*. Basel, 1555.
43. Colles CJ: On stenosis of the trachea after tracheotomy for croup and diphtheria. *Ann Surg* 1886; 3:499.
44. Kato I, Uesugi K, Kikuchihara M, et al: Tracheostomy: The horizontal tracheal incision. *J Laryngol Otol* 1990; 104:322.
45. Bjork VO, Engstrom CG: The treatment of ventilatory insufficiency after pulmonary resection with tracheostomy and prolonged artificial ventilation. *J Thorac Surg* 1955; 20:151.
46. Bercic J, Pocajt M, Drzecnik J: The influence of tracheal vascularization on the optimum location, shape and size of the tracheostomy in prolonged intubation. *Resuscitation* 1978; 6:131.
47. Fry TL, Jones RO, Fischer ND, et al: Comparisons of tracheostomy incisions in a pediatric model. *Ann Otol Rhinol Laryngol* 1985; 94:450.
48. Levermore JN, Milne DM: Tracheo-graft fistulae following pharyngo-laryngo-oesophagectomy: A cause and its prevention. *J Laryngol Otol* 1979; 93:293.
49. Fairshter RD, Liff MO, Wilson AF: Complications of long tracheostomy tubes. *Crit Care Med* 1976; 4:271.
50. Snyder GM: Individualized placement of tracheostomy tube fenestration and in-situ examinations with the fiberoptic laryngoscope. *Respir Care* 1983; 28:1294.
51. Klausen NO, Lomholt N, Qvist J: Dilatation of the trachea treated with the NL-tracheostomy tube. *Crit Care Med* 1982; 10:52.
52. Gunawardana RH: Experience with tracheostomy in medical intensive care patients. *Postgrad Med J* 1992; 68:338.
53. Goldstein SI, Breda SD, Schneider KL: Surgical complications of bedside tracheotomy in an otolaryngology residency program. *Laryngoscope* 1987; 97:1407.
54. Hawkins ML, Burrus AF, Treat RC, et al: Tracheostomy in the intensive care unit: A safe alternative to the operating room. *South Med J* 1989; 82:1096.
55. Hunt JL, Purdue GF, Gunning T: Is tracheostomy warranted in the burn patient? Indications and complications. *J Burn Care Rehabil* 1986; 7:492.
56. Lesnik I, Rappaport W, Fulginiti J, et al: The role of early tracheostomy in blunt, multiple organ trauma. *Am Surg* 1992; 58:346.
57. Rodriguez JL, Steinberg SM, Luchetti FA, et al: Early tracheostomy for primary airway management in the surgical critical care setting. *Surgery* 1990; 108:655.
58. Dunham CM, LaMonica CA: Prolonged tracheal intubation in the trauma patient. *J Trauma* 1984; 24:120.
59. Desjardins R, Desjardins G, Blanc VF, et al: Nasotracheal intubation and tracheostomy in acute epiglottitis and laryngotracheal bronchitis. *J Otolaryngol* 1978; 7:230.
60. Lund T, Goodwin CW, McManus WF: Upper airway sequelae in burn patients requiring endotracheal intubation or tracheostomy. *Ann Surg* 1985; 201:374.
61. Astrachan DI, Kirchner JC, Goodwin WJ Jr: Prolonged intubation vs. tracheostomy: Complications, practical and psychological considerations. *Laryngoscope* 1988; 98:1165.
62. Boyd SW, Benzel EC: The role of early tracheostomy in the management of the neurosurgical patient. *Laryngoscope* 1992; 102:559.
63. Miller JD, Kapp JP: Complications of tracheostomies in neurosurgical patients. *Surg Neurol* 1984; 22:186.
64. Cooper JD, Grillo HC: The evolution of tracheal injury due to ventilatory assistance through cuffed tubes: A pathologic study. *Ann Surg* 1969; 169:334.
65. Neiderman MS, Ferranti RD, Zeigler A, et al: Respiratory infection complicating long-term tracheostomy. *Chest* 1984; 85:39.
66. Neiderman MS, Merrill WW, Ferranti RD, et al: Nutritional status and bacterial binding in the lower respiratory tract in patients with chronic tracheostomy. *Ann Internal Med* 1984; 100:795.
67. Snow N, Richardson JD, Flint LM: Management of necrotizing tracheostomy infections. *J Thorac Cardiovasc Surg* 1981; 82:341.
68. Cole AGH, Kerr JH: Paratracheal abscess after tracheostomy. *Intensive Care Med* 1983; 9:345.
69. Rubio PA, Sharman TL, Farrell EM: Tracheostomy tube insertion in the pretracheal fascia. *Int Surg* 1982; 67(Suppl):418.
70. Arola M, Inberg MV, Sotara M, et al: Tracheo-arterial erosion complicating tracheostomy. *Ann Chir Gynaecol* 1979; 68:9.
71. Adolfsson R, Winblad B, Ostberg: Survival after haemorrhage from the brachiocephalic truncus following tracheostomy. *Acta Otolaryngol* 1975; 80:312.
72. Takano H, Ihara K, Sato S: Tracheo-innominate artery fistula following tracheostomy: Successful surgical management of a case. *J Cardiovasc Surg* 1989; 30:860.
73. Nunn DB, Sanchez-Salazar AA, McCullagh JM, et al: Tracheo-innominate artery fistula following tracheostomy: Successful repair using an innominate vein graft. *Ann Thorac Surg* 1975; 20:698.
74. Wood DE, Mathisen DJ: Late complications of tracheotomy. *Clin Chest Med* 1991; 12:597.
75. Grillo HC: Congenital lesions, neoplasms, and injuries to the trachea. In: *Surgery of the Chest*. 5th ed. Sabiston DC, Spencer FC (Eds). Philadelphia, WB Saunders, 1990, pp 335-371.
76. Sellery GR, Worth A, Greenway RE: Late complications of prolonged tracheal intubation. *Can Anaesth Soc J* 1978; 25:140.
77. Woo P, Kelly G, Kirshner P: Airway complications in the head injured. *Laryngoscope* 1989; 99:725.
78. Oeken FW: Tracheostomy: Late complications and their treatment. *Zentralblatt Chir* 1978; 103:1169.
79. Jones JW, Reynolds M, Hewitt RL, et al: Tracheo-innominate artery erosion: Successful surgical management of a devastating complication. *Ann Surg* 1976; 184:194.
80. Sasaki CT, Horiuchi M, Koss N: Tracheostomy: Related subglottic stenosis: Bacteriologic pathogenesis. *Laryngoscope* 1979; 89:857.
81. Hsu S, Dreisbach JN, Charlifue SW: Glottic and tracheal stenosis in spinal cord injured patients. *Paraplegia* 1987; 25:136.
82. Lebowitz PW, Geller E, Andrew SK: Endotracheal balloon cuff dilatation of tracheostomal stenosis. *Anesthesiology* 1982; 57:323.
83. Grillo HC, Mathisen DJ: Surgical management of tracheal strictures. *Surg Clin North Am* 1988; 68:511.
84. Rose KG: Cicatricial stenosis in the crico-tracheal region: A new surgical approach. *HNO* 1982; 30:285.
85. Reed JP, Kempf JP, Hamelberg W, et al: Studies with transtracheal artificial respiration. *Anesthesiology* 1954; 15:28.
86. Bougas TP, Cook CD: Pressure-flow characteristics of needles

- suggested for transtracheal resuscitation. *N Engl J Med* 1960; 262:511.
87. Yealy DM, Plewa MC, Stewart RD: An evaluation of cannulae and oxygen sources for pediatric jet ventilation. *Am J Emerg Med* 1991; 9:20.
 88. Dallen LT, Wine R, Benumof JL: Spontaneous ventilation via transtracheal large-bore intravenous catheters is possible. *Anesthesiology* 1991; 75:531.
 89. Mackenzie CF, Barnas GM, Smalley J, et al: Low-flow endobronchial insufflation with air for 2 hours of apnea provides ventilation adequate for survival. *Anesth Analg* 1990; 71:279.
 90. Slutsky AS, Watson J, Leith DE: Tracheal insufflation of O₂ (TRIO) at low rates sustains life for several hours. *Anesthesiology* 1985; 63:278.
 91. Smith RB, Babinski M, Klain M, et al: Percutaneous transtracheal ventilation. *JACEP* 1976; 5:765.
 92. Jordan RC, Moore EE, Marx JA: A comparison of PTV and endotracheal ventilation in an acute trauma model. *J Trauma* 1985; 25:978.
 93. Tan SS, Dhara SS, Sim CK: Removal of a laryngeal foreign body using high frequency jet ventilation. *Anaesthesia* 1991; 46:741.
 94. Weymuller EA Jr, Pavlin EG, Paugh D: Management of difficult airway problems with percutaneous transtracheal ventilation. *Ann Otol Rhinol Laryngol* 1987; 96:34.
 95. Lassa RE, Habal MB, Ross N, et al: Rapid access airway: Surgical device and technique. *Int Surg* 1978; 63:152.
 96. Schein B, Orko R, Orsback C: Ventilation through a minitracheostomy: An experimental study in pigs. *Ann Chir Gynaecol* 1987; 76:327.
 97. Campbell CT, Harris RC, Cook MH, et al: A new device for emergency percutaneous transtracheal ventilation in partial and complete airway obstruction. *Ann Emerg Med* 1988; 17:927.
 98. Ravussin P, Freeman P: A new transtracheal catheter for ventilation and resuscitation. *Can Anaesth Soc J* 1985; 32:60.
 99. Matthews HR, Fischer BJ, Smith BE: Minitracheostomy: A new delivery system for jet ventilation. *J Thorac Cardiovasc Surg* 1986; 92:673.
 100. Mammel MC, Ophoven JP, Lewallen PK, et al: High-frequency ventilation and tracheal injuries. *Pediatrics* 1986; 77:608.
 101. Shuptrine JR, Auffant RA, Gal TJ: Cerebral and cardiopulmonary responses to high-frequency jet ventilation and conventional mechanical ventilation in a model of brain and lung injury. *Anesth Analg* 1984; 63:1065.
 102. Wei HF, Jin SA, Bi HS: Hemodynamic effects of high frequency jet ventilation during acute hypovolemia. *J Tongji Med Univ* 1991; 11:174.
 103. Lindholm P, Outzen KE: Pneumothorax during jet ventilation in laryngobronchoscopy. *Ugesk Laeger* 1991; 153:199.
 104. Bourreli B, Bigot A, Wesoluch M, et al: Pneumomediastinum and subcutaneous emphysema after translaryngeal jet ventilation. *Ann Fr Anesth Reanim* 1984; 3:377.
 105. Yealy DM, Plewa MC, Reed JJ, et al: Manual translaryngeal jet ventilation and the risk of aspiration in a canine model. *Ann Emerg Med* 1990; 19:238.
 106. Golden GT, Fox JW, Edlich RF: Emergency tracheostomy. *Am J Surg* 1976; 131:766.
 107. Ivatury R, Siegel JH, Stahl WM, et al: Percutaneous tracheostomy after trauma and critical illness. *J Trauma* 1992; 32:133.
 108. Schachner A, Ovil Y, Sidi J, et al: Percutaneous tracheostomy: A new method. *Crit Care Med* 1989; 17:1052.
 109. Bodenham A, Cohen A, Webster N: A clinical evaluation of the "Rapitrach": A bedside percutaneous tracheostomy technique. *Anaesthesia* 1992; 47:332.
 110. Ciaglia P, Firsching R, Syniec C: Elective percutaneous dilatational tracheostomy: A new simple bedside procedure: Preliminary report. *Chest* 1985; 87:715.
 111. Leinhardt DJ, Mughal M, Bowles B, et al: Appraisal of percutaneous tracheostomy. *Br J Surg* 1992; 79:255.
 112. Toye FJ, Weinstein JD: Clinical experience with percutaneous tracheostomy and cricothyroidotomy in 100 patients. *J Trauma* 1986; 26:1034.
 113. Ciaglia P, Graniero KD: Percutaneous dilatational tracheostomy: Results and long-term follow-up. *Chest* 1992; 101:464.
 114. Hutchinson RC, Mitchell RD: Life-threatening complications from percutaneous dilatational tracheostomy. *Crit Care Med* 1991; 19:118.
 115. Hazard P, Jones C, Benitone J: Comparative clinical trial of standard operative tracheostomy with percutaneous tracheostomy. *Crit Care Med* 1991; 19:1018.
 116. Paul A, Marelli D, Chiu RC, et al: Percutaneous endoscopic tracheostomy. *Ann Thorac Surg* 1989; 47:314.
 117. Fisher EW, Howard DJ: Percutaneous tracheostomy in a head and neck unit. *J Laryngol Otol* 1992; 106:625.
 118. Bodenham A, Diament R, Cohen A, et al: Percutaneous dilatational tracheostomy: A bedside procedure on the intensive care unit. *Anaesthesia* 1991; 46:570.

CHAPTER 81

Proximal Airway Disorders in the Pediatric Patient

Richard E. Weibley, MD, MPH

Airway pathology is a common problem for physicians caring for pediatric patients. The proximal airway from the nares to the carina is often involved. Although the number of different disorders that can occur in the proximal airway of pediatric patients is large, careful attention to history and physical findings coupled with an understanding of anatomy and pathophysiology should allow a clinician to localize the lesion generally and begin treatment while investigating and defining the specific diagnosis.

ANATOMY

The processes of development as well as absolute size differences are important for understanding the causes of proximal airway failure and their appropriate treatment in infants, children, and adolescents. Because newborn infants have a relatively small mandible and a large tongue that crowds and fills the oropharynx, infants are primarily obligate nose breathers during quiet respiration.¹ As the mid-face and mandible grow, the relative difficulties of oropharyngeal breathing in infancy disappear.

The epiglottis in infancy is relatively long and stiff, U or V shaped, and angulated approximately 45° from the anterior pharyngeal wall owing to the close proximity of the hyoid bone and thyroid cartilage.² As growth occurs, separation of the hyoid and the thyroid cartilage results in a more erect position of the epiglottis. By adolescence, the epiglottis assumes the flattened and flexible adult anatomy, positioned parallel to the base of the tongue.

The laryngeal structures also change with growth, moving lower in the neck with age.¹ In term infants, the laryngeal inlet is at the level of the cervical vertebral interspace C3-4, whereas in adults it rests at interspace C4-5. As an infant grows, the vocal cords change direction and shape with increasing length, primarily as a result of growth of the anterior ligamentous portion. In adults, the narrowest portion of the respiratory tract is generally the laryngeal inlet, whereas in infants and young children it is usually the laryngeal outlet, the inferior ring portion (arch) of the cricoid cartilage. With growth the ring enlarges, the cricoid plate assumes a more vertical position, and this anatomic point of narrowing disappears.

The histologic characteristics of the larynx remain constant from infancy to adulthood. Squamous epithelium cov-